

Unusual Clinical Presentation of a Case of Localized Plasma Cell Gingivitis

SHRUTHI S., SHEELA KUMAR GUJJARI, USHA HEGDE, VEERENDRA KUMAR S.C.

ABSTRACT

Plasma cell gingivitis, which is also called atypical gingivitis or plasma cell gingivostomatitis, is a rare benign inflammatory condition of unknown aetiology. It presents clinically as a diffuse, erythematous and papillary lesion of the gingiva, which frequently bleeds, with minimal trauma.

This is a case report of a 57 year old female patient, where dental plaque was the aetiological factor for plasma cell gingivitis with an unusual presentation.

Key Words: Plasma cell gingivitis, Gingiva, Plaque

INTRODUCTION

Plasma cell gingivitis which is also called atypical gingivitis or plasma cell gingivostomatitis [1], is a rare benign inflammatory condition of unknown aetiology [2]. It presents clinically as a diffuse, erythematous and papillary lesion of the gingiva, which frequently bleeds, with minimal trauma [3]. Gingival ulcerations are rare [4]. Plasma cell gingivitis may produce the swelling of the gingiva and the upper lip, and a burning sensation on the tongue [5]. Plasma cell gingivitis is so named because of the presence of an abundant plasma cell infiltrate within the connective tissue [3].

This condition is more prevalent in young women [1].

It usually affects the maxillary gingiva, although reports have shown that it affects the mandibular gingiva also [6].

It has been reported to be asymptomatic [3] most of the times.

Plasma cell gingivitis is thought to be a hypersensitivity response; the aetiology for plasma cell gingivitis has been allergens such as mint, cinnamon which is present in the toothpaste and chewing gum. Other categories of this disease can be neoplastic lesions or lesions of unknown causes [5].

There also have been reports of bacterial plaque acting as an allergen [8].

A case report of a 57 year old female patient, where dental plaque was the aetiological factor for plasma cell gingivitis with an unusual presentation, is being reported here.

CASE REPORT

A 57 year old female patient was referred from the Department of Oral Medicine and Radiology to the Department of Periodontics for oral prophylaxis.

On intra-oral examination, the oral hygiene status of the patient was found to be poor, with a plaque and gingival index of > 3. There was a solitary swelling which measured 6mm × 8mm on the lingual side of the mandibular anteriors. The lesion was pale pink, sessile and firm in consistency. It was non-tender on palpation and there was no bleeding on provocation in the same area.

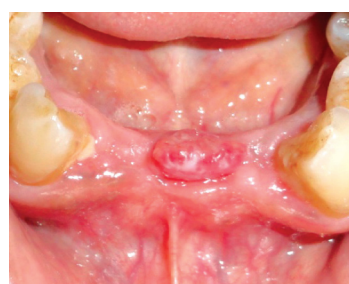The patient was asymptomatic and gave a history of first noticing the swelling 2 months back. It was reported to be small in size and to have slowly increased to the present size.

The patient gave a medical history of being hypotensive since 2 years and of not being on any medication for the same. There was no other relevant medical history.

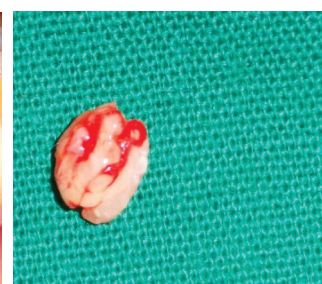
The routine haematological investigations were found to be normal and the radiological examination revealed severe bone loss with respect to the lower anteriors.

The patient was given a differential diagnosis of pyogenic granuloma.

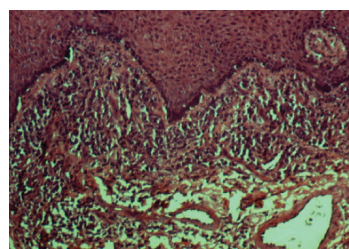
The line of treatment was extraction of the lower anteriors, as it had a poor periodontal prognosis.



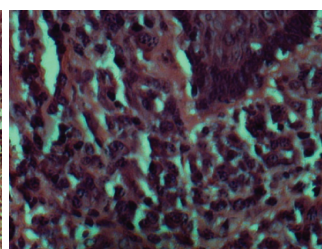
[Table/Fig-1]: Solitary swelling measuring 6mm by 8mm



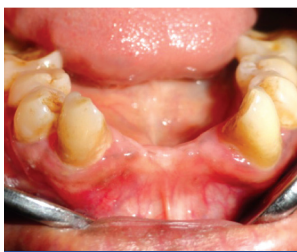[Table/Fig-2]: Excised lesion



[Table/Fig-3]: Histologic appearance of plasma cell gingivitis showing epithelium and connective tissue stroma (H&E original magnification × 4)



[Table/Fig-4]: Section shows numerous plasma cells (H & E, original magnification × 40)



[Table/Fig-5]: Months post operative

The patient was recalled for phase I therapy. In the next visit, the swelling was surgically excised and sent for biopsy.

The patient was recalled after a week and the healing was found to be satisfactory.

HISTOPATHOLOGY

Histopathology revealed the presence of stratified, squamous, parakeratinized, hyperplastic epithelium overlying a densely infiltrated connective tissue. There was a dense infiltrate of plasma cells which were arranged in the form of sheets and a few areas showed the presence of Russell bodies. A mixed inflammatory infiltrate and blood vessels were also seen.

So, a diagnosis of plasma cell gingivitis was given.

DISCUSSION

Plasma cell gingivitis is an uncommon condition which is characterized by a sharply demarcated, erythematous, oedematous, diffuse gingivitis which often extends into the mucogingival junction [2]. In the present case, the presentation was unusual, as it was a solitary growth with a papillary surface.

The appearance of this case of plasma cell gingivitis on the mandibular gingiva is inconsistent with the results of previous reports, where it affected the free and attached anterior gingiva of the maxilla. However, there are reports of cases which affected the mandibular gingivae [6]. In the present case, it affected neither the free or attached gingiva of the mandible, but was present on the mandibular anterior ridge.

The aetiology of plasma cell gingivitis is not clear, but due to the obvious presence of the plasma cells, many authors are of the opinion that it is an immunological reaction to allergens which may be present in toothpaste, chewing gum, mint pastels, certain foods and oral care products [6]. Mint which is present in toothpastes and chewing gum is a putative allergen [3]. Cinnamonaldehyde, which is usually added to dentrifices to mask the unpleasant taste of pyrophosphate, has also been associated with the development of plasma cell gingivitis [4]. Cases which were related to the use of herbal toothpaste have been reported [4]. It has been suggested that some herbs and strong spices such as chilli, pepper and cardamom may be important factors which cause plasma cell gingivitis [12]. However, it is likely that more than one aetiological factor is involved in the pathogenesis. Other than the lesions which are caused by allergens, plasma cell gingivitis can present as a neoplastic lesion or as lesions of unknown causes [5].

In the present case, patient did not give any history of usage of any known allergens, but the patient had a poor oral hygiene. Hence in this case the bacterial plaque could have acted as an allergen causing plasma cell gingivitis.

The differential diagnosis of the condition is very important because of its similarity to some other aggressive conditions. Localized plasma cell gingivitis presents as a soft, erythematous gingival swelling which has to be differentiated from the reddish purple appearing pyogenic granuloma, which is more commonly encountered in the oral cavity. Both the lesions are asymptomatic, are commonly seen in the facial aspect of the anterior maxilla and bleed on slight manipulation.

The lesions of pyogenic granuloma are usually pedunculated and the surface of the lesions shows ulceration, which may not be a feature of plasma cell gingivitis.

The histopathological differential diagnoses were pemphigus, lichen planus, leukaemia, plasma cytoma and myeloma [4]. Pemphigus and lichen planus was excluded, based on the negative "Nikolsky's Sign", biopsy and history. The absence of the atypical plasma cells ruled out malignancies such as multiple myeloma and extra medullary plasmacytoma. The normal haematological investigations, along with the biopsy, ruled out leukaemia as the diagnosis.

As these possibilities were ruled out in the present case and based on the histopathological reports such as epithelial hyperplasia and dilated vascular channels in the underlying lamina propria, along with a chronic inflammatory infiltrate with a predominance of plasma cells, favoured the diagnosis of localized plasma cell gingivitis.

In long standing cases of chronic periodontitis, we do see the presence of an increased amount of plasma cells, which is a generalized condition. In the present case, the lesion was localized, which is uncommon.

The present case was managed by thorough oral hygiene reinforcement and phase I therapy. The lesion was excised and sent for biopsy. The patient is kept in the maintenance phase.

Traditionally, the management of patients with plasma cell gingivitis has been symptomatic and plaque control and conventional therapies alone will not cure the disease. The patients should be instructed to keep a complete dietary history. Possible allergens should be eliminated in an attempt to discover the underlying cause. If no answer is apparent, then an extensive allergy testing and an elimination diet can be undertaken.

Patients in whom no underlying cause could be discovered have been treated with topical or systemic immunosuppressive medications, but with variable results [2]. In the present case, the patient is on regular follow up and in case the lesion recurs, then the patient will be advised to undergo patch testing and an immunofluorescence test. The allergic testing would demonstrate a polyclonal mixture of plasma cells and a normal profile on plasma electrophoresis [11]. Further, T cell marker analysis by direct immunofluorescence will establish the condition of the lesion as neoplastic or reactive in origin [3].

However, in spite of all the evaluations and therapeutic interventions, some patients do not respond to the treatment and no cause for the disease can be identified.

CONCLUSION

The case which is presented here highlights the occurrence of localized plasma cell gingivitis in the anterior region of the mandible, which is not a very common site. There was also no history of the usage of any known allergens. As the oral hygiene status of the patient was bad, the microbial plaque which could have been present, could have acted as an allergen in the development of plasma cell gingivitis. Although there is a pre-dominance of plasma cells in chronic periodontitis which is a generalized condition, the present case showed localization of the lesion, which is uncommon.

Even though the general oral hygiene status of the patient was bad, the reason for it to be present as a localized swelling in the present case rather than as a diffuse edematous and erythematous lesion is not understood.

Although plasma cell gingivitis presents as a localized swelling very rarely, it should be considered in the differential diagnosis of localized swellings of the gingiva.

REFERENCES

- [1] Shafer, Hine, Levy. Shafer's Textbook of Oral Pathology; Fifth Edition; p. 546.
- [2] Vaidya P, Gupta U. Plasma cell gingivitis – A case report. *Indian Journal of Dental Sciences* 2010; 2:23-25.
- [3] Pantanwala A, Fischer EW, Chapple LLC. Plasma cell gingivitis which affects the gingiva, the palatal mucosa and the laryngeal cords. *Perio* 2006; 3:123-28.
- [4] Sukumaran A. Plasma Cell gingivitis among herbal toothpaste users: A report of three cases. *The Journal of Contemporary Dental Practice* 2007; 8:60-66.
- [5] Sollecito TP, Greenberg MS. Plasma cell gingivitis: report of two cases. *Oral Surg Oral Med Oral Pathol* 1992;73: 690-93.
- [6] Marker P, Krogdahl A. Plasma cell gingivitis which is apparently related to the use of khat: report of a case. *Br Dent J* 2002;192(6):311-13.
- [7] Lubow RM, Cooley RL, Hartman KS, McDaniel RK. Plasma-cell gingivitis. Report of a case. *J Periodontol* 1984;55(4):235-41.
- [8] Hedin CA, Karpe B, Larsson A. Plasma-cell gingivitis in children and adults. A clinical and histological description. *Swed Dent J* 1994;18 (4):117-24.
- [9] Palmer RM, Eveson JW. Plasma-cell gingivitis. *Oral Surg Oral Med Oral Pathol* 1981;51(2):187-89.
- [10] Miller RL, Gould AR, Bernstein ML. Cinnamon-induced stomatitis venenata; Clinical and characteristic histopathological features. *Oral Surg Oral Med Oral Pathol* 1992;73(6):708-16.
- [11] Damm DD, Allen CM, Bougout JE. Periodontal Diseases In Oral and Maxillofacial Pathology, Second edition, India, Saunders, An Imprint of Elsevier, p. 141-42
- [12] Serio FG, Siegel M, Slade BEP: Plasma cell gingivitis of unusual origin: A case report. *J Periodontal* 1999; 62(6):390-93.

AUTHOR(S):

1. Dr. Shruthi S.
2. Dr. Sheela Kumar Gujjari
3. Dr. Usha Hegde
4. Dr. Veerendra Kumar SC

PARTICULARS OF CONTRIBUTORS:

1. Corresponding Author.
2. Department of periodontology,
JSS Dental College and Hospital a Constituent
of JSS University, SS Nagar,
Mysore 570014.
3. Department of Oral Pathology
JSS Dental College and Hospital a Constituent
of JSS University, SS Nagar,
Mysore, India - 570014.
4. Department of Periodontology
JSS Dental College and Hospital a Constituent
of JSS University, SS Nagar,
Mysore, India - 570014.

NAME, ADDRESS, TELEPHONE, E-MAIL ID OF THE CORRESPONDING AUTHOR:

Dr Shruthi S., III MDS
Department of Periodontology
JSS dental college and hospital a Constitute of JSS univeristy
SS Nagar, Mysore 570014.
E-mail: docshruthi1984@gmail.com/sheelagujjari@hotmail.com
Phone no: 9886824276

DECLARATION ON COMPETING INTERESTS:

No competing Interests.

Date of Submission: **Jun 21, 2011**
Date of peer review: **Aug 29, 2011**
Date of acceptance: **Sep 04, 2011**
Date of Publishing: **Oct 05, 2011**